

Breast Specific Gamma Imaging in the Management of Indeterminate Lesions Detected on Breast MRI

Leora Lanzkowsky, MD, Deborah Rubin, MD, Karen Fu, MD, Adam Brochert, MD, Nelda Mullins, ARRT(R) (M) (N)
Eisenhower Medical Center, Rancho Mirage CA

INTRODUCTION

Breast MRI utilization is increasing as a result of the 2007 ACS guidelines for breast cancer screening. Indeterminate MRI leads to increased costs and time constraints on our health system, as well as indefinable patient anxiety. Breast Specific Gamma Imaging (BSGI) may mitigate the need for biopsy after an indeterminate MRI, thereby reducing the number of false positive biopsies, and resultant strain on the patient and health system.

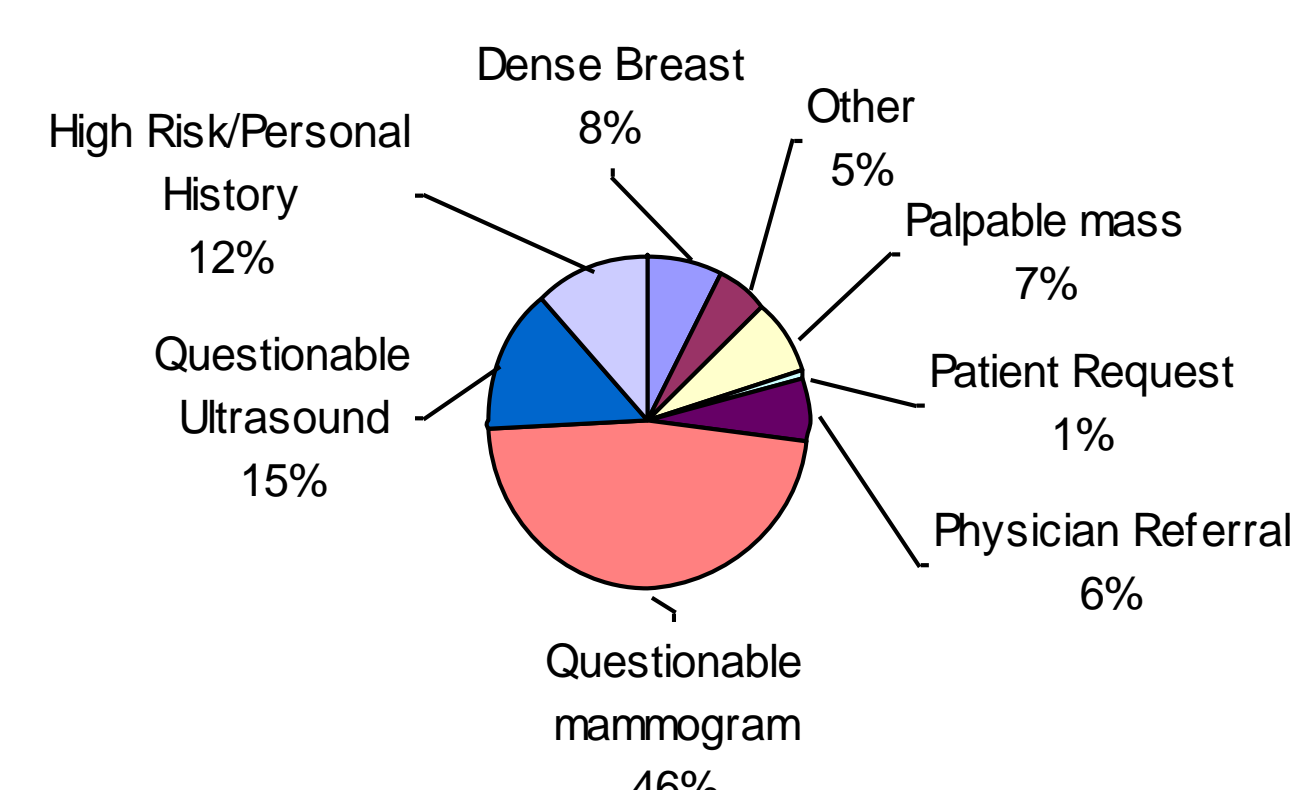
MATERIALS AND METHODS

BSGI was performed using the Dilon Breast Specific Gamma Camera with 30 mc of Tc99m injected and acquisition of the images immediately. MRI using a Breast Coil on a Siemens (Espree, Symphony) 1.5 Tesla magnet with gadolinium and standard breast protocol. All patients have had BSGI and MRI in addition to mammography and ultrasound. All indications were included. Biopsies were performed in all BSGI positive scans. Biopsies were conducted in patients with negative BSGI scans when indicated by other modalities. Lesions with pathology requiring surgical excision are considered positive.

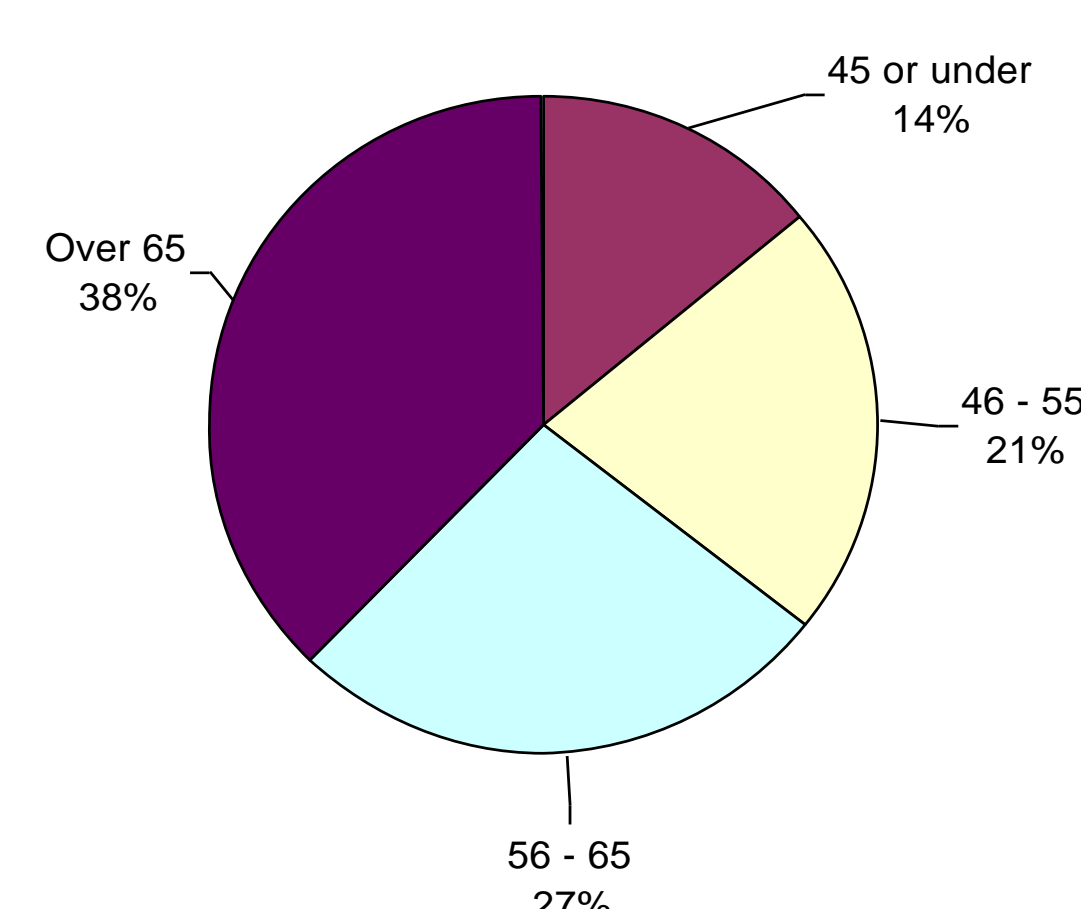
POPULATION

The Eisenhower Medical Center has been utilizing BSGI for 14 months as a problem solving tool in cases where mammography and/or ultrasound did not provide a clear diagnosis. To date, there have been 288 patients with a total of 446 areas of concern who have had BSGI performed as part of the diagnostic work up. The patient population by age and indication are listed in the tables below. This work is concentrated on the sub-population who have received both BSGI and MRI as part of their clinical work up.

Reason for Exam



Patient Age



RESULTS

There were a total of 60 patients with 81 lesions examined by both BSGI and MRI. In this group, there were 38 lesions with indeterminate findings on MRI (BIRADS 0 or 3) and there is pathologic confirmation for 17 of these lesions. The resulting pathology includes: 1 papillary carcinoma, 1 atypical ductal hyperplasia and 15 benign lesions. Both of the high risk lesions were positive on BSGI along with 4 benign lesions (false positives). BSGI was also indeterminate in 5 lesions, but true negative in 6.

- Correctly ruled out the need for biopsy or follow up for 6 lesions (35%)
- Correctly ruled in the need for intervention in 2 lesions (12%)
- Resulted in no change in management for 5 lesions (29%)
- Resulted in benign biopsy for 4 lesions (24%).

	BSGI	MRI
Sensitivity	88%	85%
Specificity	76%	70%
PPV	56%	50%
NPV	95%	93%
Accuracy	79%	74%
FNR	3%	4%

EXAMPLE CASE

PREOPERATIVE WORKUP

HISTORY - 46 year old with multiple suspicious appearing mammographic and sonographic lesions bilaterally. Mammogram - heterogeneously dense breast tissue. Right Breast: architectural distortion at 1 o'clock anterior depth; focal asymmetry 11 o'clock mid depth. Left Breast: 2.5cm focal asymmetry with heterogeneous calcifications at 2 o'clock posterior depth; density with a cluster of calcifications at 1 o'clock anterior depth; 10 cm area of segmental calcifications at 1 o'clock middle depth.

US - Right Breast: 9mm lobulated region at 9 o'clock middle depth with mixed echogenicity and increased vascularity; 8mm lesion with irregular margins at 1 o'clock retroareolar region also vascular. Left Breast: 3.5 cm lobulated region in the 1 o'clock position posterior depth; additional hypoechoic areas in the retroareolar region and at 1 o'clock in the posterior depth.

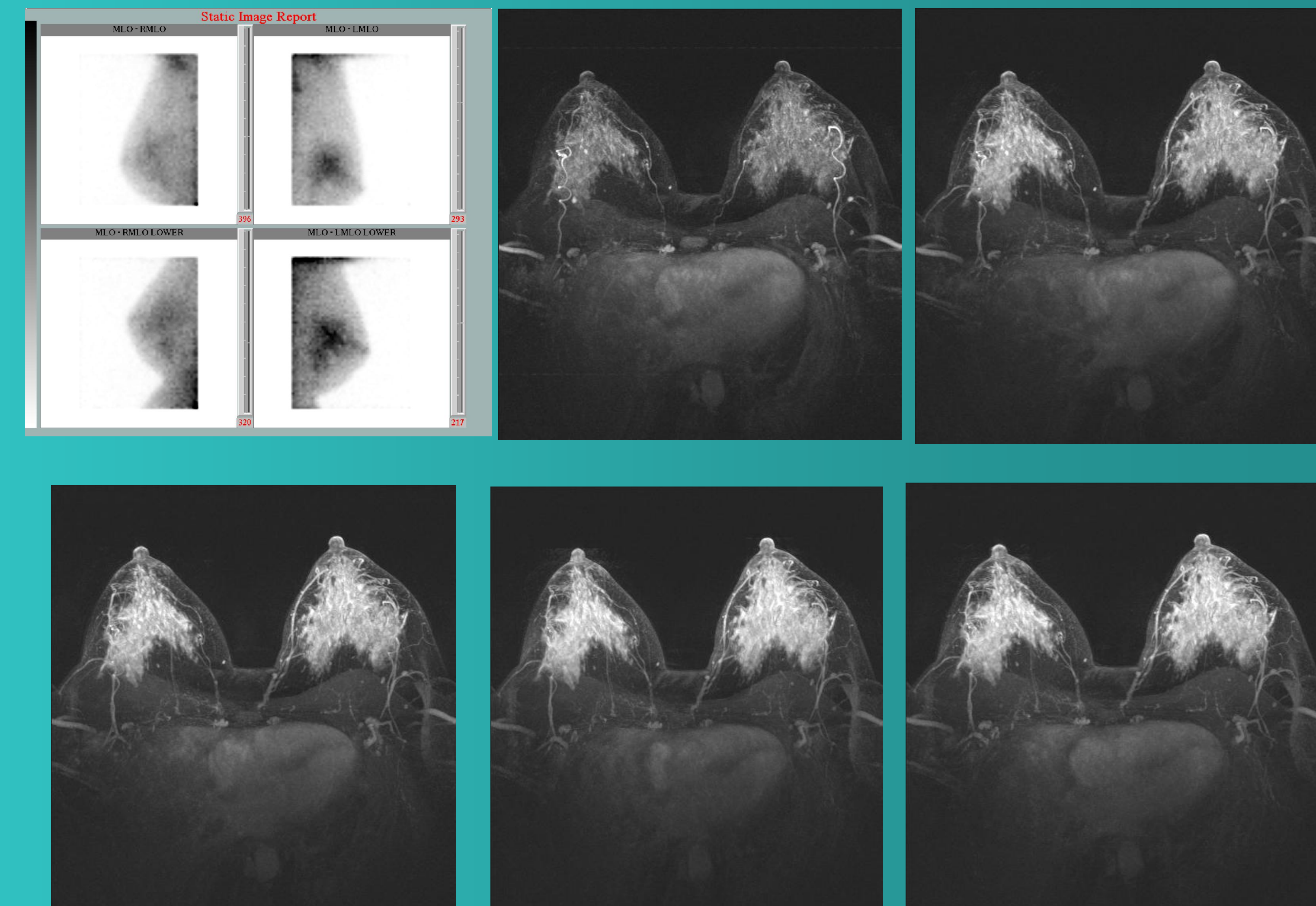
MRI - dense parenchymal pattern limits the assessment of individual lesions. No specific lesions noted in the right breast. The left breast contains a 7 x 6mm area of abnormal enhancement in the 3 - 4 o'clock position 2.5 cm from the nipple.

EXAMPLE CASE CONTINUED

Left breast needle biopsies - Stereotactic core: at 1 o'clock contains fibroadenoma and ductal hyperplasia; at 2 o'clock atypical ductal hyperplasia; 3 o'clock atypical ductal hyperplasia.

Right breast biopsy - ultrasound guided at 1 o'clock yields fibrocystic changes.

Preoperative dilemma - multiple suspicious lesions; very complex imaging studies and multiple ADH findings at needle biopsy. Is mastectomy needed?



BSGI - The right breast is negative with diffuse heterogeneous distribution, but no abnormal focal tracer accumulation. There is abnormal regional uptake in the upper outer quadrant of the left breast in the area of biopsy confirmed atypical ductal hyperplasia. This asymmetric uptake is consistent with disease process. No new areas or findings are evident.

Pathology - left breast mastectomy found multifocal low grade ductal carcinoma in situ from 1 to 6 o'clock.

CONCLUSIONS

As the use of Breast MRI increases, so does the number of false positive biopsies. Methods to reduce the number of false positive biopsies are needed. BSGI can corroborate a benign second look ultrasound, mitigate the need for continued short interval follow-up MRI studies, or confirm the need for a biopsy. Early indicators suggest that the use of BSGI can decrease the false positive biopsy rates resulting from Breast MRI. A large prospective study on this topic is needed.