

Mammographically Occult Reoccurrence

George Washington University Medical Center - Washington, D.C.

Breast-Specific Gamma Imaging with the Dilon 6800

Clinical History

Follow up for left breast lumpectomy and ductal carcinoma diagnosis 4 years prior. Patient notes a palpable nodule below the surgical site near the midline.

Mammogram

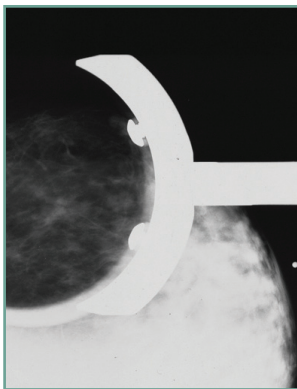
Left breast: no evidence of discrete mass. Benign microcalcifications and surgical site scarring noted. Normal scar tissue with adjacent glandular tissue. Spot compression image shown provides optimal regional contrast. BIRADS 2.

Breast-Specific Gamma Imaging

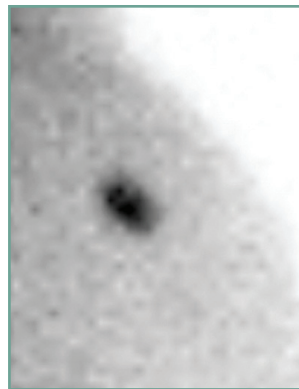
Left breast: both MLO and CC view note very highly contrasting foci near the mediolateral midline and superior to the nipple line. This area corresponds to the biopsy site for previous lumpectomy 4 years prior. Such focal intensity in a surgical scar is highly indicative of tumor re-growth. POSITIVE.

Histopathology Findings

Infiltrating lobular carcinoma.



LSP mammogram



LMLO BSGI



LCC BSGI

Because BSGI is a physiological image of the breast, it provides excellent diagnostic capability for patients with post-surgical and/or post-therapeutic densities. BSGI utilizes a radiotracer and images breast cancer by its increased metabolic activity.

