

Tissue Distortion Secondary to Breast Cancer Treatment – BSGI Detects Recurrence

Eisenhower Medical Center, Rancho Mirage, CA

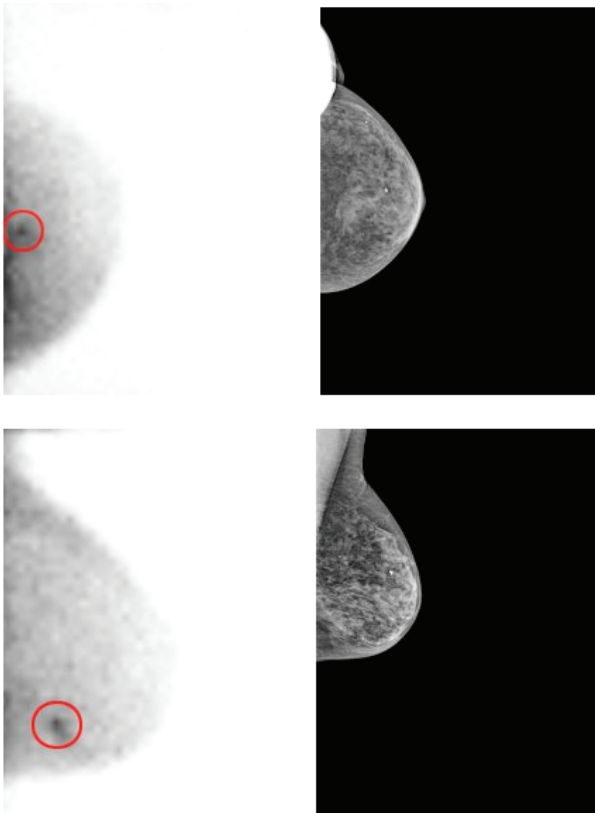
Breast-Specific Gamma Imaging with the Dilon 6800

Clinical History

72 year old presents for a six month follow up. History of right breast malignancy 12 years prior treated with partial mastectomy and radiation therapy. Six months ago, she experienced a milky/bloody discharge from the right breast. Ultrasound and mammography demonstrated a mass at the retroareolar 4 o'clock position of the right breast, which was biopsied - benign findings.

Mammogram

Bilateral heterogeneously dense breast tissue. Right breast had postoperative changes and was smaller than the left. Multiple benign appearing calcifications present in the left breast. There is also a benign asymmetry in the left breast, middle depth central to the nipple only seen in the CC view. Ultrasound is recommended for better evaluation of the right breast lumpectomy site and the contralateral asymmetry.



Ultrasound

There are multiple indeterminate hypoechoic areas in the upper outer quadrant of the left breast at posterior depth. Patient is claustrophobic and refuses MRI. BSGI is suggested for further work up.

BSGI IMPACT AND PATIENT DIAGNOSIS

There was a 6 x 7 mm highly focal intensity in the left breast at the 6 o'clock position slightly posterior to middle depth. Highly suspicious for malignancy.

Second look ultrasound was utilized to localize and biopsy this area. Ultrasound indicated a 10 x 4 mm hypoechoic lesion of mixed BSGI abnormality. This is suggestive of malignancy. Ultrasound guided core biopsy and subsequent lumpectomy revealed a 7mm infiltrating ductal carcinoma.

Patient case histories courtesy of Eisenhower Medical Center, Rancho Mirage, CA.

BSGI detected a 7mm occult ductal carcinoma in a patient with a complex work up and dense breasts.

