

# Abnormal Mammogram with Negative BSGI

George Washington University Medical Center - Washington, D.C.

## Breast-Specific Gamma Imaging with the Dilon 6800

### Clinical History

Positive family history of breast cancer, prior mammograms indicated BIRADS 2 bilateral, stable breast nodule referred to as fibroglandular densities.

### Mammogram

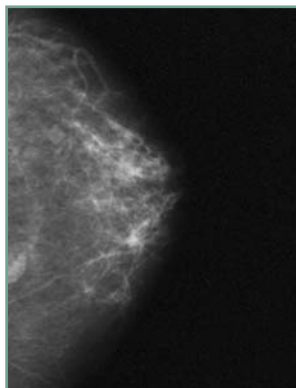
Left breast, 1 cm mass in the inferior aspect of the left breast. BIRADS 4.

### Breast-Specific Gamma Imaging

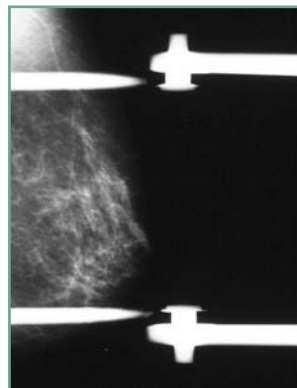
Left breast shows very low contrasting focal uptake in the posterior aspect of the MLO, not demonstrated in the CC. Given its low intensity, the lack of visualization in the CC view and the lack of corresponding radiodensity in the mammogram, the uptake is considered negative. Slightly increased posterior saturation in the CC view, consistent with cardiac shadow. No foci noted. NEGATIVE.

### Histopathology Findings

Benign lymph node.



LCC mammogram



LMLO mammogram mag view



LCC BSGI



LMLO BSGI

Cardiac Shadow: Posterior saturation of images particularly noted in the left breast CC view. This increased saturation is due to the high intensity of scatter radiation from the cardium.

The functional imaging of BSGI complements the anatomic imaging of x-ray mammography; consistently providing higher specificity than other breast imaging modalities.



Dilon Technologies LLC

12050 Jefferson Avenue; Newport News, VA 23606

Phone: 757.269.4910; Fax: 757.269.4912; www.dilon.com

