

False Negative Biopsy

West Valley Imaging - Las Vegas, NV

Breast-Specific Gamma Imaging with the Dilon 6800

Clinical History

82 year-old female with a history of right breast calcifications and benign biopsy, receiving six-month follow-up mammogram.

Mammogram

Little change from six month prior mammogram. Continued development of microcalcifications with an area of irregularity and clips noted. Suggest biopsy.

Breast-Specific Gamma Imaging

Significantly increased focal uptake of radiotracer corresponding to the location of the calcifications noted in the mammogram: suggestive of malignant process. Open biopsy of the region recommended.

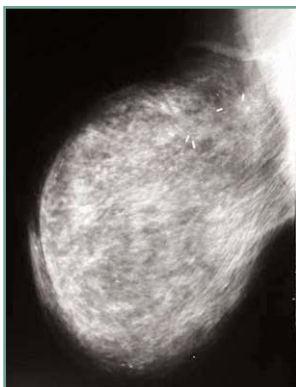
Histopathology Findings

Biopsy 1

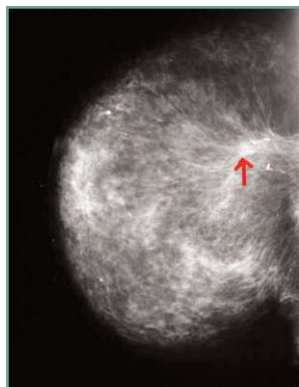
Technically successful needle biopsy with vascular calcifications and no evidence of malignancy. Post-biopsy images indicate migration of the clip.

Biopsy 2

Open biopsy of the area of microcalcifications. Tissue samples indicating ductal carcinoma.




RML0 mammogram



RCC mammogram



RML0 BSGI



RCC BSGI

Without the use of BSGI, this patient would not have been recommended for open lumpectomy. This carcinoma had been missed by previous lumpectomy.

